

RIDGE AUGMENTATION WITH
IMMEDIATE IMPLANT PLACEMENT
USING A HIGH-DENSITY TITANIUM-
REINFORCED PTFE MEMBRANE.

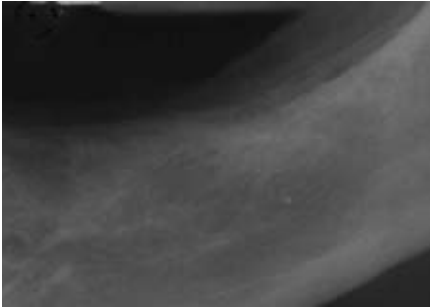


Fig 1

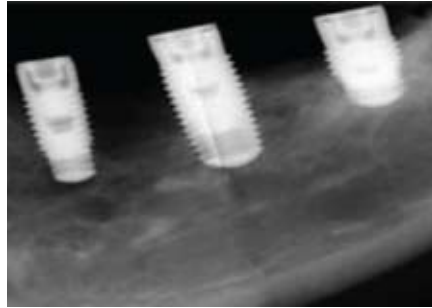


Fig 2

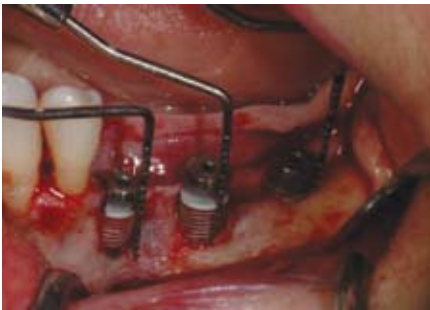

Fig 3

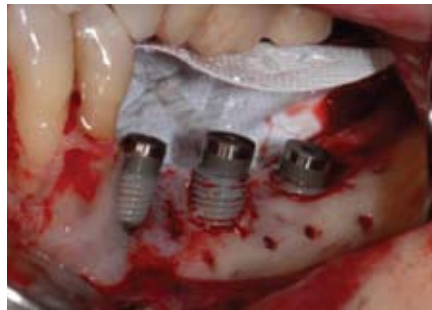

Fig 4

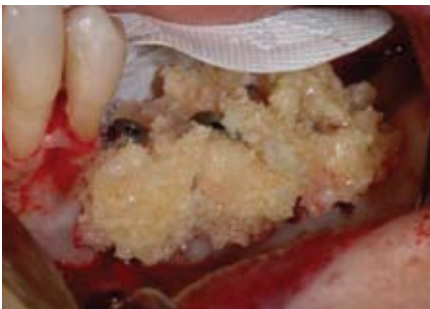

Fig 5

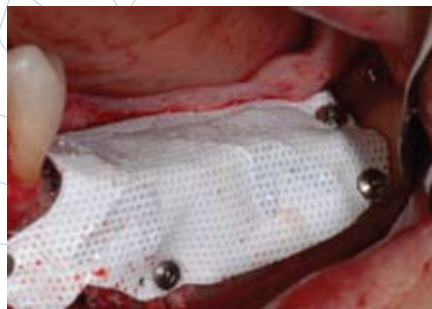

Fig 6

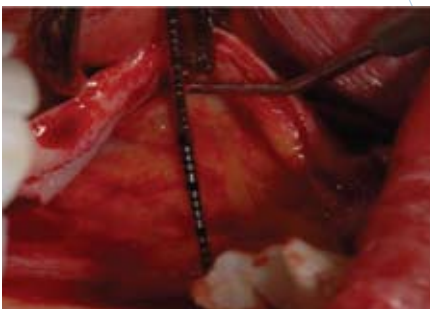


Fig 7

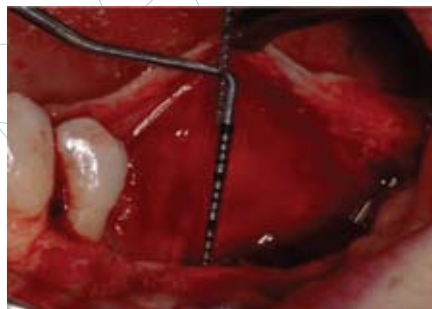

Fig 8

This is a 49 year old female who presented for implant placement in the left posterior mandible. Preoperative radiographs reveal inadequate bone height for ideal implant placement and restoration (Fig 1).

Three tapered implants were placed at second bicuspid, first molar and second molar areas, and the vertical defect was measured from crestal height to the neck of the implant (Fig 2 and 3). The defect measurements at the implant positions were 9 mm, 8 mm and 4 mm respectively. The implant measurements were 3.7 mm x 10 mm, 4.7 mm x 11.5 mm and 4.7 mm x 8 mm, respectively. The alveolar ridge was decorticated and a high-density titanium-reinforced PTFE membrane (Cytoplast® Ti-250 XL) was secured lingually with two pins (Fig 4). This membrane configuration is ideal to cover three implants. The membrane was then bent to a desired three-dimensional shape to provide stability while utilizing the implants as tenting support.

A combination (50:50 ratio) of mineralized cortical and cancellous allograft was hydrated with PRGF and placed around the implants and to the desired crestal height (Fig 5). The membrane was then draped over the graft and trimmed 1 mm from the adjacent tooth and secured with three pins buccally and two pins crestally (Fig 6).

Advancement of the buccal flap is accomplished by the use of a periosteal releasing incision along the full length of the flap. Care is taken to avoid damaging the neurovascular bundle (Fig 7). On the lingual side a new technique developed by the author for the extension of the flap was used (Fig 8). (Ronda M., Stacchi C. Management of coronally advanced lingual flap in regenerative osseous surgery: a case series introducing a novel technique. International Journal of Periodontics & Restorative Dentistry. In press)

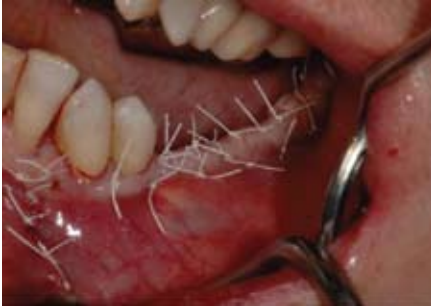

Fig 9

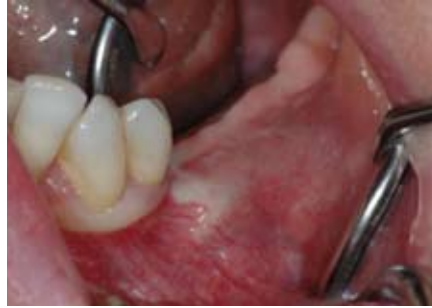

Fig 10

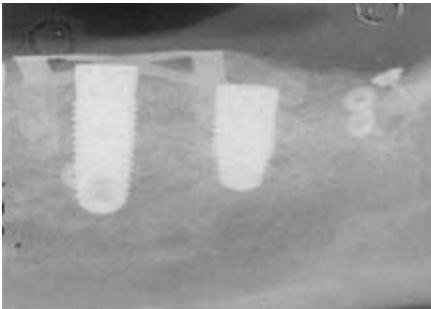


Fig 11

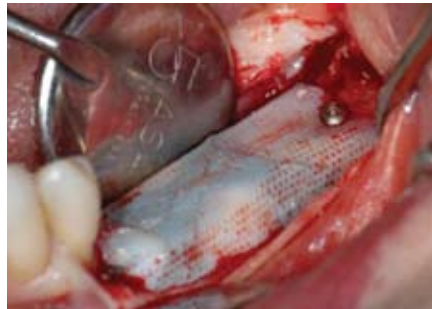

Fig 12

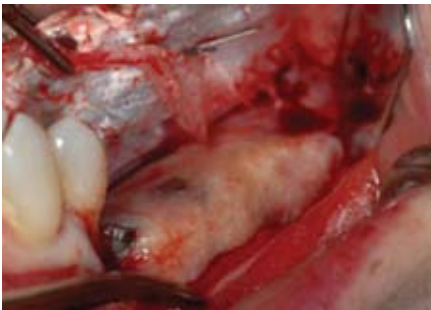


Fig 13

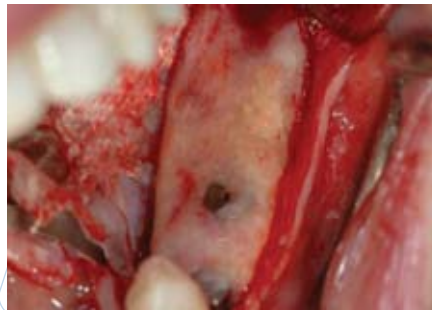


Fig 14

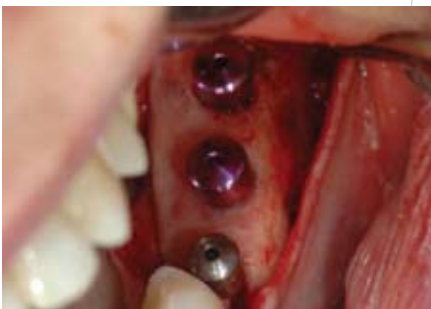

Fig 15

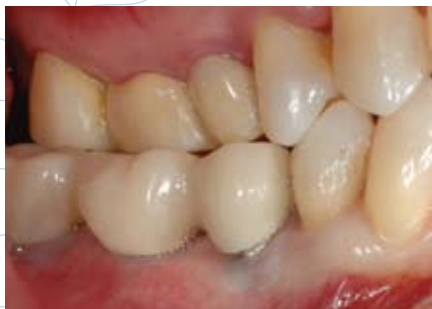

Fig 16

Primary closure was achieved using 3-0 and 4-0 PTFE sutures (Cytoplast® PTFE Suture) (Fig 9). The sutures were removed at twelve days, and the soft tissue demonstrated healing without signs of inflammation (Fig 10).

At three months, the postoperative radiograph provides evidence of increased alveolar height with this technique (Fig 11). After four months of healing, the augmented site was exposed with a mid-crestal incision (Fig 12). The membrane was removed, revealing an increase in ridge height (Fig 13). Removal of the dense PTFE membrane was greatly simplified due to the limited soft tissue ingrowth into the barrier.

The presence of compact bone can be seen overlying the implants (Fig 14). The excess bone covering the implants was removed and healing caps were placed (Fig 15). After soft tissue healing, the restorative components were placed and a temporary bridge was seated (Fig 16).

SUMMARY

This case demonstrates the successful augmentation of an edentulous posterior mandible in combination with implant placement. The use of a combination cortical and cancellous allograft, hydrated with PRGF, and coverage with a high-density titanium-reinforced PTFE membrane resulted in regeneration of vital bone of sufficient volume and height. This was accomplished in a single surgical procedure, eliminating the need for autogenous block grafting.

Cytoplast® is a registered trademark of Osteogenics Biomedical, Inc.